

Personal View

ORAL REHABILITATION ON SMALL SUBSTANCE LOSS CASES

Norina Consuela Forna

*Professor of Faculty of Dental Medicine,
University of Medicine and Pharmacy "Gr.T. Popa", Iași, Romania*

Author for correspondence:
Professor Norina Consuela Forna,
Faculty of Dental Medicine, University of Medicine and Pharmacy "Gr.T. Popa",
Str. Universitatii, nr. 16, cod 700115 ,Iași, Romania,
e-mail: medden_decanat@mail.umfiasi.ro

Abstract

The purpose of this study consists of the identification of implantologic and prosthetic methods and techniques used in substance loss rehabilitation, associated with identifying the specific biomaterials in perfect accordance with each case particularities, without leaving aside the bone-tissue deficiency etiology. A representative number of clinical cases were selected, cases which are relevant for the chosen theme. The possibility of reconstructing the natural parameters of the edentulous alveolar ridge areas is various, starting with augmentation materials of the autogenous and heterograft type biomaterials(Bio-Oss, Grafton, Cerasorb si MBCP) including the mixing of these two types of biomaterials, and going to epitheses, which are the best choice for complex substance loss.

Key-words: *Oral rehabilitation, biocompatibility, facial prosthesis, implanto-prosthetic therapy.*

Rezumat

Obiectivul acestui studio constă in identificarea metodelor protetice și implantologice folosite in esența reabilitării, concomitant cu identificarea biomaterialelor specifice recomandate in fiecare caz după particularități, fara deficiențe ale țesutului osos.

A fost selectat un număr reprezentativ de cazuri clinice, relevante pentru acest subiect.

Posibilitatea reconstrucției parametrilor naturali al edentației alveolare este variată, după diversificarea materialelor grefoanelor autogene și heterogene, adică biomateriale ca)Bio-Oss, Grafton, Cerasorb si MBCP, incluzând și mixuri din două biomateriale, care susțin ipoteza că acestea ar putea fi o variantă recomandabilă. pentru astfel de cazuri.

Cuvinte-cheie: *celule stem medulare osoase, interdisciplinaritate, angiogeneză.*

INTRODUCTION

Oral rehabilitation is the integrative *personal concept* reuniting each segment of the dento-maxillar apparatus affected by edentation under its various clinical forms, without eluding the complications induced and the influence played by the general status within the chosen therapeutic algorithm.

The purpose of this study is to analyze the extent to which the therapeutic solutions within the oral rehabilitation get closer to the therapeutic ideal, as well as the modality in which the reality of the clinical cases reflected in the particular aspects of the prosthetic field, the general condition, the socio-economical criteria influence the clinic finality.

The implantologic and prosthetic territory represents a domain of excellence in operations of complex oral-maxillar-facial rehabilitation, and it is materialised during a specific and very important stage included in this complex algorithm (1).

The causes of substance loss are represented by oral-maxillar-facial trauma, by cyst and tumour removal, etiologies which confer a high degree of difficulty to these cases (2).

The rehabilitation of the substance losses has an ascendant way starting from intra-orally limited defects up to aspects having a crescendo character with the perturbation of the functions of the stomatognathic system without eluding two well delimited forms, namely the mutilating resorbtion and atrophy processes triggering serious facial modifications and the absence of a significant bony capital caused by the tumor ablation.

PURPOSE

The purpose of this study consists of the identification of implantologic and prosthetic methods and techniques used in substance loss rehabilitation, associated with identifying the specific biomaterials in perfect accordance with each case particularities, without leaving aside the bone-tissue deficiency etiology.

The scientific activity unfolded abides by the objectives provided in the initial plan aiming at finishing the mathematical modeling in full compliance with the real clinical situations of a group of patients diagnosed with substance losses, of

different sizes anchored in the intra or oral territory, their solving and the biomaterials involved being different.

MATERIAL AND METHODS

For the three - dimensional reconstruction of different types of intra and extra-oral maxillofacial substance losses we used the universal programme Amira for 3D reconstructions for any type of Computer Tomograph.

A representative number of clinical cases were selected, cases which are relevant for the chosen theme. The reconstruction of substance loss is of critical importance in re-establishing the optimal parameters which characterise the edentulous alveolar ridge areas.

The possibility of reconstructing the natural parameters of the edentulous alveolar ridge areas is various, starting with augmentation materials of the autogenous and heterograft type biomaterials, including the mixing of these two types of biomaterials, and going to epitheses, which are the best choice for complex substance loss.

RESULTS

The dispersion of forces at the level of the mucous-bony support is fully linked to the masticatory force generated by the natural dentition, by diverse types of fixed restorations as well as by the mobile prostheses inducing low tensions at the level of the antagonistic arch, the presence of the silicon material proposed by us as lining material for these types of prostheses after the finishing of the adhesion mechanism between the two biomaterials being in full compliance with the biomechanical principle of reducing pressures at the mucous-bony level. A high frequency of the analyzed cases is represented by substance losses at the mandibular level, the analysis by finite element revealing tension concentrators at the level of the edges of substance defect (Fig. 1).

Aspects of mathematical modeling for a substance loss at mandibular level highlighting the influence of action of the muscular factor over the future reconstruction (Fig. 2).

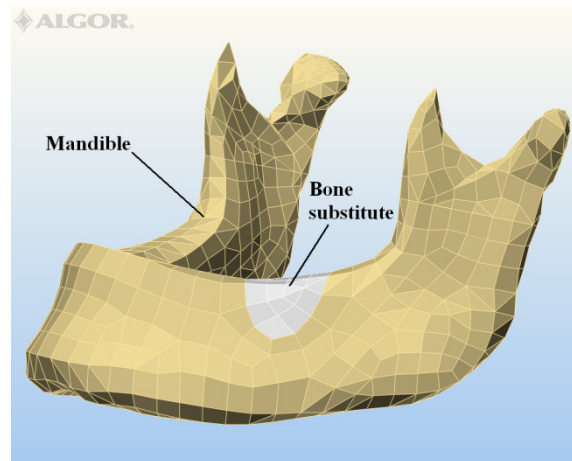


Fig. 1.Aspect of substance defect

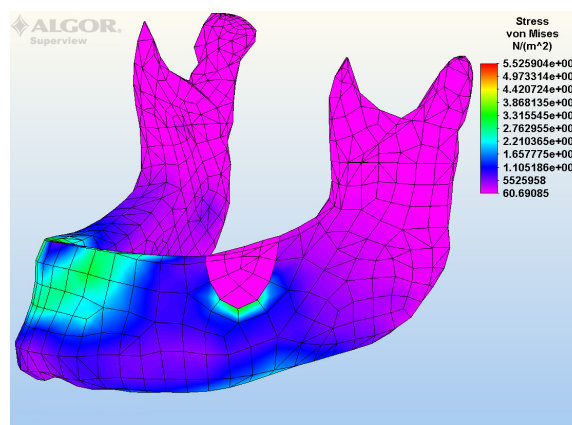


Fig. 2.Aspect of time with the augmentation stage

When it comes to the biomechanical and aesthetic reconstruction of the arcade, in the majority of the cases the implantologic variant was preferred, followed by the fixed or removable prosthesis, which were realised either on a separate, post-augmentation stage, or in the same time with the augmentation stage (2).

The most frequent losses of substance are the intraoral ones, their immediate solution being shown in these two clinical cases - the loss of substance is a consequence of the oral maxillofacial surgery intervention, the excision of pseudo tumor formations (Fig. 3).

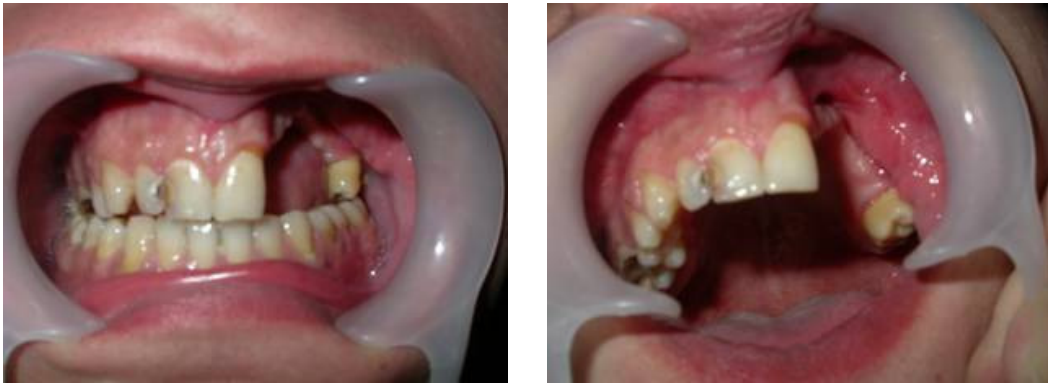

Fig. 3. Aspects of intraoral losses of substance

In the both cases, we elaborated epitheses which aim the restoring of the alveolar and dental arch continuity, equally assuring aesthetic and functional rehabilitation by covering the loss of substance.

An important aspect of epithesis elaboration is the fidelity of the previous morphology restoring, which shows incongruence in both cases.

These fixed prosthetic constructions are the results of a rigorous technological algorithm, the metallic frame will need special retentions in order to apply the aesthetic compound; the acrylic material can be flexible, protecting the mucosseous support from traumatism of the aliments passing (Fig. 4).

The final retention of the epithesis is achieved by including the marginal teeth, assuring the restoring of the anterior dental arch, thus leading to the augmentation of the prosthetic construction stability (Fig. 5).

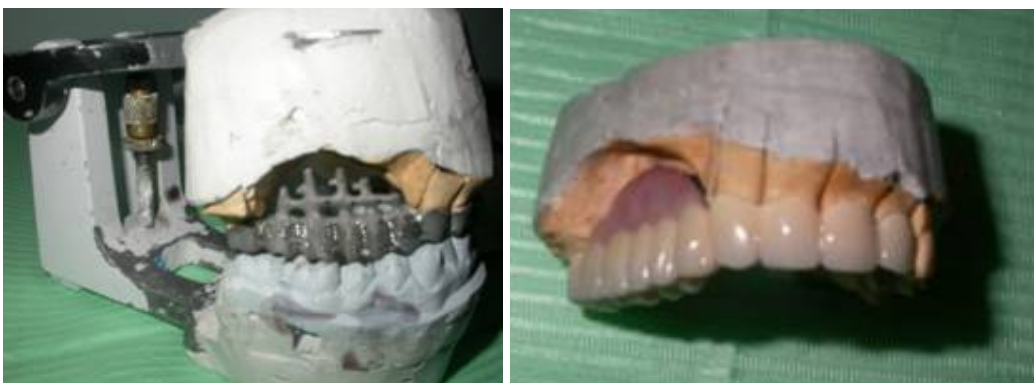

Fig. 4. The epithesis framework

Fig. 5. Final aspect of the epithesis

The morpho-functional and bio-mechanical characteristics of the clinical situation which ultimately resulted, after the quantification of the clinical and para-clinical data, pleaded for the election of 11 Perio implants, type X class, represented another cases, very important for this subject. The distribution of the implantations in the two dials was divided in 5 implants with a diameter of 3,3 and 4 mm, with lengths of 10, 11,5, 13 and 15 mm, with the full consensus of the dimensions of the bone support and of the organic structures substituted in the dial 1:14, 15, 16, 17, 18. At the second dial's level 6 implantations were applied, having the diameter of 3,3 and lengths of 10, 13, 15 mm, corresponding to the dental elements 22, 23, 24, 25, 26, 27 (Fig. 6).

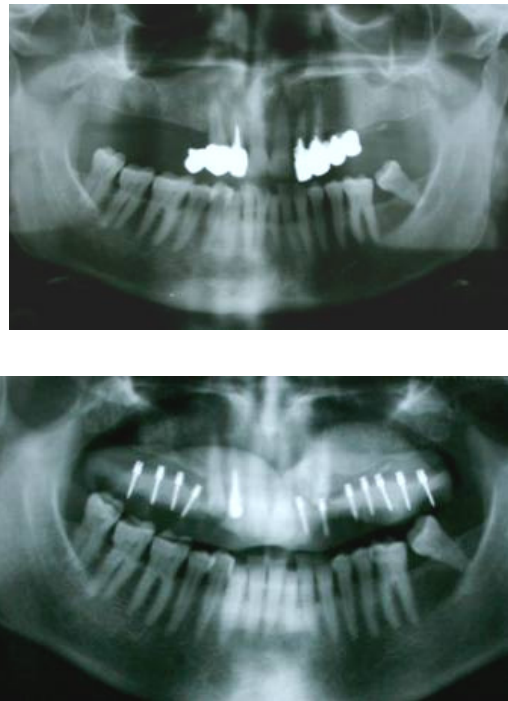


Fig. 6. The radiological aspects before and after implantation

The optimal results were obtained through the rigorous compliance with the bio-mechanical principals and the correlation of the increasing method in the same session with surgical insertion of the implantations, based on the usage of the Cerasorb bio-material, having a granulation of 150-500 μm , with an inorganic, that reunites the derivatives of the calcium and phosphate, with a high degree of bio-compatibility (Fig. 7).

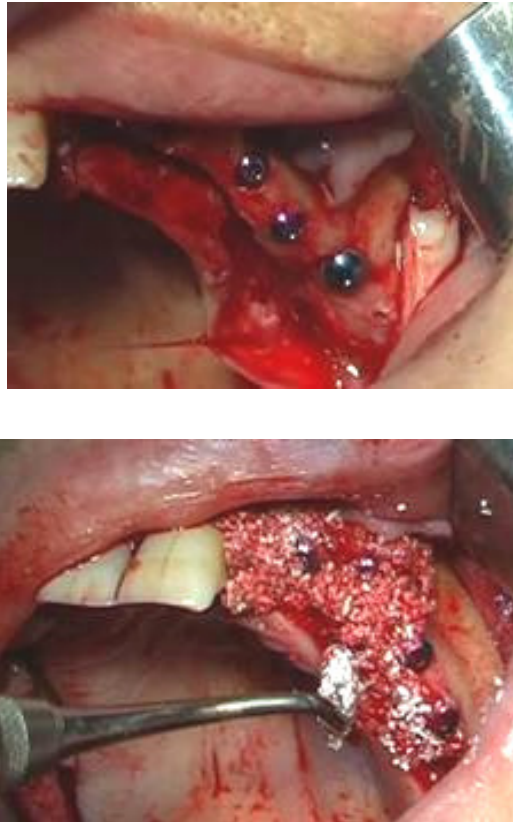


Fig. 7. Aspects of augmentation with Cerasorb

The confirmation from the images of the clinical and para-clinical jaws offer the radiography of a deficient jaw prosthetic field, the remaining odonothoparodontal elements being characterized by negative clinical and biological parameters. The degree of the bone absorption, which stood at the basis of the pro-prosthetic preparation stage, will offer the optimal for the prosthetic bed's design (3).

An important aspect in the case's success was represented by the increase of the ridge in the frontal zone, with the help of the Bio-Oss and of the Titan-made membrane. The manual labour was done at the same time with the implant, the intervention pleading for the advantage of the limitation for the surgical timing.

The balance between success and failure had relatively limited lines, but for the present case the age and the reaction of the tissue were in favour of the post-operation evolution.

The Bio-Oss is substitute of the natural bone, osteo-inductiv that leads to the controlled bone increase at the level of the prosthetic fields characterised by a parodontic affection or by substance losses at the bone level (Fig. 8). This therapeutic selection was based on the inducement of the bone crest at the situs' level, where it was transplanted (4). This decision was correlated with the application of the metal membrane, which is going to adapt at the future volume of the crest (Fig. 9).

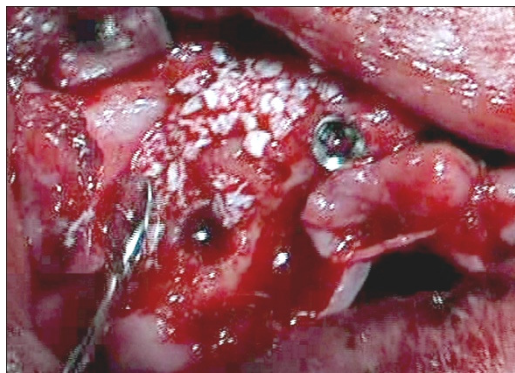


Fig. 8. Aspects of augmentation with Bio-Oss

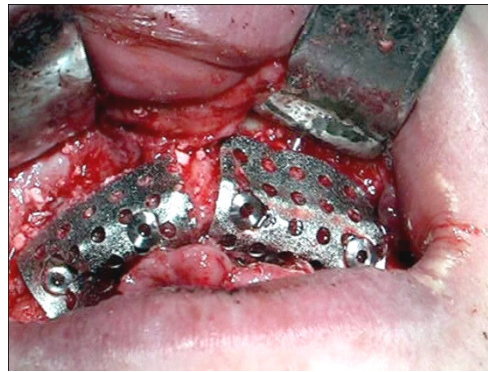


Fig. 9. Aspects of Titan mesch in rehabilitation of frontal ridge

The immediate prosthetic was an important stage after the implant and increase, the final prosthetic offering the facial harmony and the confidence of the patient itself (5).

CONCLUSIONS

The intraoral losses of substances is a sever mutilation and its elective immediate treatment indication is the elaboration of epitheses.

The importance of the substance loss rehabilitation – a stage which is precedent or concomitent to that of implantologic therapy – is reflected in the appreciation of the resorption and atrophy process on the edentulous crest level and this appreciation has a definytory influence upon accomplishing the final stage of the clinical case.

The mathematical modeling of the real clinical situations offers optimal data to choose the treatment solution fully compliant with the parameters characterizing the substance loss, the type of biomaterial involved in the structure of the prosthetic substitute, and in the case of maxillofacial prostheses an important role is played by the fixing means.

REFERENCES:

1. Forna N, Burlui V. *Clinical Guidelines and Principles in the Therapy of Partial Extended Edentation*. Iași: Ed. Apollonia, 2001, 470-477.
2. Norina Forna, *Evaluarea Starii De Sanatate Afectate Prin Edentatie*, Editura Demiurg, 2007 ISBN 978-973-152-017-9, Carte editata cu sprijinul Autoritatii Nationale pentru Cercetare Stiintifica, 25-26
3. Norina Forna, *Protetica Dentara*, Vol I, Vol II ,Editura Enciclopedica, 2011.
4. Norina Forna, Magda Antohe, *Reabilitarea Pierderilor De Substanta* Editura Demiurg, 2007, ISBN 978-973-152-035-3, Carte editata cu sprijinul Autoritatii Nationale pentru Cercetare Stiintifica, 180-186
5. Büchter A, Kleinheinz J, Wiesmann HP, Jayaranan M, Joos U, Meyer U. Interface reaction at dental implants inserted in condensed bone. *Clin Oral Implan Res* 2005; 16: 509–517.
6. *** www.clinical-house.com

7. Sethi A, Kaus T, Sochor P. The use of angulated abutments in implant dentistry: five-year clinical results of an ongoing prospective study. *Int J Oral Max Implan* 2000; 15: 801–810.

Eger DE, Gunsolley JC, Feldman S. Comparison of angled and standard abutments and their effect on clinical outcomes: a preliminary report. *Int J Oral Max Implan* 2000; 15: 819–823