

THE USE OF INTRAOPERATIVE ULTRASOUND IN ABDOMINAL SURGERY

Vasile SÂRBU¹, Guido TORZILLI², Florin BOTEĂ¹

Abstract. *Introduction* Intraoperative ultrasound (IOUS), introduced in abdominal surgery by Makuuchi is an important imaging tool in the operating room with standardized applications for diagnosis and ultrasound guided procedures during surgery. *Material and Method* The studied group consisted of 449 patients operated between January 2002 - January 2009 for hepato - biliary, splenic and renal pathology, of which 93 were treated and prospectively studied in the 2nd Clinic of Surgery, Clinical Emergency Hospital (Constanta), and 356 patients with liver pathology were treated, and retrospectively and prospectively studied in the Department of Liver Surgery, Humanitas Clinical Institute (Milan). *Results.* In Constanta study group, IOUS was performed in 77 cases with liver pathology (82,8%) (48 cases with hydatid cyst, 9 with abscesses, 12 with metastasis, 7 with hemangiomas and 1 with hepatocellular carcinoma), 9 cases with biliary disease (9,7%) (8 cases with lithiasis, one with cholangiocarcinoma), and 6 cases with renal lithiasis (6,4%); there were no major complications and mortality. In the Milan group, IOUS with and without contrast detected a total number of 1068 lesions (average 3, 2; median 2; range 1 - 48). The postoperative morbidity rate was 23,2% (83 cases); major complications were recorded in 6,4% (23 cases) and minor complications in 16,8% cases (60 cases). The reintervention rate was of 1,4% (5 cases). The postoperative mortality rate was 1,1% (4 cases). *Conclusions.* IOUS is a method of diagnosis and guidance of surgical procedures, which has to be part of the modern abdominal surgery arsenal in generally, and of hepatic surgery in particular, being optimally exploited when performed by the surgeon.

Keywords: intraoperative ultrasound, abdominal surgery, diagnosis.

1. Introduction

Intraoperative ultrasound (IOUS), introduced in abdominal surgery by Makuuchi [1] is an important imaging tool for the operative room with standardized applications for diagnosis and also with ultrasound guiding procedures for surgical techniques. That is the reason for which IOUS has a significant importance in the management and treatment of abdominal pathology [2]. IOUS is used nowadays in completing some extracorporeal diagnostic methods (such as CT, RMN), existing significant proofs that IOUS, with and without contrast, is superior to those, with higher sensitivity and specificity in detecting certain lesions [3]. Nowadays,

¹ 2nd Clinic of Surgery-Clinical Emergency Hospital, Constanta; Ovidius University of Constanta

² Liver surgery department - Humanitas Rozzano Clinical Research Institute; Milan University of Medicine

Corresponding author: Botea Florian, Clinical Emergency Hospital of Constanta, B-dul Tomis, nr 145, Constanta, e-mail:boteaflorian@yahoo.com

the diagnostic performances of the preoperative imagistic techniques have IOUS as a reference in a series of diseases.

The indications of the intraoperative abdominal ultrasound include the following [4]:

1. Staging the abdominal malignant tumors, especially in metastasis, whose staging can be underestimated by the preoperative imagistic techniques;
2. Establishing the resectability of hepatic and pancreatic tumors by studying their relationships with vascular and biliary structures;
3. Management of liver hydatid cyst, depicting its topography and relationship with vessels and biliary tree;
4. Exploration of the biliary tract for gallstones or tumors;
5. Location of endocrine and pancreatic tumors;
6. Evaluation of acute and chronic pancreatitis, including pseudocysts, with identification of their mature regions of the wall for drainage, and evaluation of the peripancreatic fluid collections;
7. Detection of ureteral and renal stones and localization of renal tumors;
8. Viewing the digestive tract tumors;
9. Guiding the diagnostic biopsy.

2. Material and Method

Patients

The studied group consisted of 449 patients operated between January 2002 – January 2009 for hepato - biliary, splenic and renal pathology, of which 93 were treated and prospectively studied in the 2nd Clinic of Surgery, Clinical Emergency Hospital (Constanta), and 356 patients with liver pathology were treated, and retrospectively and prospectively studied in the Department of Liver Surgery, Humanitas Clinical Institute (Milan).

Constanta study group

IOUS was carried out in 93 patients admitted in Clinical Emergency Hospital Constanta, out of which 87 patients were operated in the 2nd Clinic of Surgery for hepato - biliary and splenic pathology, and 6 patients were operated in the Clinic of Urology for renal lithiasis. Of the 86 patients operated for hepato - biliary pathology, 77 had hepatic pathology and 9 cases with biliary pathology.

Milan study group

The studied group was made of 356 consecutive patients, operated for liver tumors in the Department of Liver Surgery, Humanitas Clinical and Research Institute (Milan, Italy), during January 2002 – January 2009. Of these, 180 patients, operated between January 2002 and September 2006, were studied retrospectively, and 177 patients, operated between October 2006 and January 2009, were studied prospectively.

3. Method

Constanta study group

Intraoperative ultrasounds were performed with a GE Logiq 500 ultrasound, with a T-shaped transducer - T739 - with frequencies which vary between 5 and 10 MHz. The ultrasound exploration was preceded by intraoperative inspection and palpation.

Milan study group

IOUS was carried out with an Aloka SDD 5500 (Aloka ltd; Tokyo, Japan) ultrasound and then with an Aloka Alpha 10 (Aloka ltd; Tokyo, Japan) ultrasound, equipped with a standard convex probe of 3-6 MHz and with two intraoperative probes of 7,5-10 MHz, one T-shaped and the other micro convex (so called Makuuchi's probe). The tumor staging was completed by contrast enhanced intraoperative ultrasound (CEIOUS) using a standard convex probe of 3-6 MHz and with harmonic frequencies of 1,88 - 3,76 MHz.

4. Results

Constanta study group

The studied group consisted of 93 patients admitted in Clinical Emergency Hospital Constanta, 87 patients in the 2nd Clinic of Surgery for hepato - biliary and/or splenic pathology, and 6 patients in the Clinic of Urology for renal lithiasis. (**Table 1**).

The liver pathology studied by IOUS (77 patients) is presented in **Table 2**. Liver hydatid disease represented the main liver disease in our study (62,3%).

Cases	Fluid collections		Tumoral lesions			TOTAL
	Hydatic cyst	Abscess	Metastasis	Heman-gioma	Hepatocellular carcinoma	
Nr.	48	9	12	7	1	77
%	62,3	11,7	15,6	9,1	1,3	100,0

Table 1. The distribution of cases with intraoperative ultrasound in function of pathology. * one case with splenic pathology (multiple hydatid cysts) had associated hepatic pathology (multiple hepatic cyst).

Cases	Pathology				Total
	Hepatic	Biliary	Splenic	Renal	
Nr	77	9	2*	6	93
%	82,8	9,7	2,1	6,4	100

Table 2. The distribution of cases with hepatic intraoperative ultrasound in function of pathology.

The applications of intraoperative diagnostic ultrasound in liver pathology are presented in **Table 3**. The differential diagnosis with the IOUS between the infected hepatic hydatidic cyst and the hepatic abscess has recorded a sensitivity and specificity of 100%. We specify that in the metastatic disease the intraoperative ultrasound (IOUS) has revealed 5 previously undetected lesions (at 4 patients), between 3 and 24mm in diameter. The only major intraoperative incident was represented by a hemorrhage which necessitated blood transfusion. In the studied group there were no postoperative major complications or intra- and postoperative mortality.

Diagnostic liver IOUS	Applications		Number of cases	%
In the complete diagnosis of diseases	Staging hepatic cysts according to Gharbi's classification		48	100,0 ¹
	Complications of hydatidic cysts	Cyst infection	7	14,6 ¹
		Biliary-cystic fistulas	6	12,5 ¹
	Tumor staging: detecting de novo CRM		4	33,3 ²
In differential diagnosis of focal liver lesions	Infected hydatidic cyst versus hepatic abscess		9	15,8 ³
	Hepatic metastasis versus hemangioma		7	36,8 ⁴
Visualization of lesions relations with important anatomical hepatic elements	In fluid collections	Hydatidic cyst	17	35,4 ¹
		Abscess	1	11,1 ⁵
	In tumor lesions (CRM)		6	50,0 ⁶

Table 3. The applications of diagnosis intraoperative ultrasound in hepatic surgery. The percentages were calculated according to the total number of studied patients with hydatidic cyst¹, with hepatic metastasis of colo-rectal origin (CRM)², ones with hydatidic cyst and ones with abscess³, ones with CRM and hemangioma⁴, with abscess⁵, and with CRM⁶

The applications of the IOUS in guiding the surgical maneuvers are presented in **Table 4**.

Applications of IOUS in guiding surgical manoeuvres	Number of cases	%	
Detecting impalpable, deep, small size lesions and/or of similar consistency with the hepatic parenchyma	In fluid collections	24	42.1 ¹
	Hydatic cyst	21	43.8 ²
	Abscess	3	33.3 ³
	In tumoral formations	3	15.0 ⁴
	CRM	3	25.0 ⁵
Ultrasound guided approach of fluid collections	Directly ultrasound guided approach	11	19.3 ¹
	Hydatic cyst	8	16.7 ²
	Abscess	3	33.3 ³
	Transcavitar ultrasound guided approach	5	8.8 ¹
	Hydatic cyst	4	8.3 ²
	Abscess	1	11.1 ³
	Transthoracic frenotomy ultrasound guided approach	4	7.0 ¹
	Hydatic cyst	3	6.3 ²
	Abscess	1	11.1 ³
	Intraoperative PAIR approach	6	10.5 ¹
	Hydatic cyst	4	8.3 ²
	Abscess	2	22.2 ³
Ultrasound guided approach of tumoral formations (ultrasound guided resection)	Ultrasound guided hepatic resection	1	5.0 ⁴
	Hepatocellular carcinoma	1	5.0 ⁴

Table 4. Applications of intraoperative ultrasound in guiding surgical manoeuvres. Percentages were calculated reporting to the total number of fluid collections¹, of hydatic cysts², abscesses³, tumors⁴, and colorectal liver metastasis (CRM)⁵

IOUS has established the diagnosis and located the fluid collections, undetected previously by intraoperative inspection-palpation (due to consistency and interposition of a portion of liver parenchyma). It also viewed their relationships with intrahepatic major vascular and biliary structures and guided the evacuatory hepatotomy (**Figure 1**).

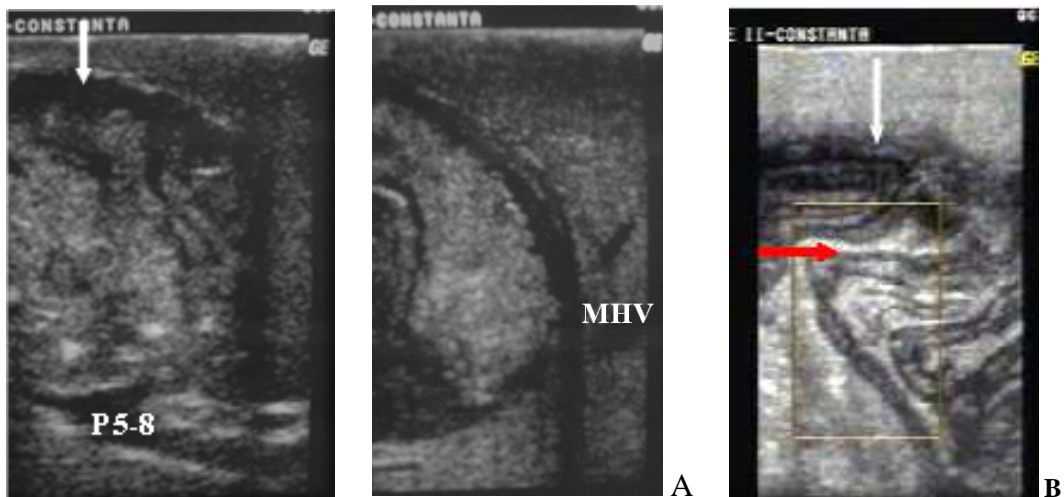


Figure 1. IOUS in infected hydatid cyst. A. IOUS in a 64 year-old patient locates the hydatid cyst situated in segments 5 and 8, in relationship with the anterior portal branch of the right portal vein (P5-8) and medial hepatic vein (MHV). B. Infected hydatid cyst, with detached and manipulated hydatid membrane (horizontal arrow). The vertical arrows indicate the level of ultrasound guided hepatotomy.

Furthermore, IOUS guided the resection of a large hepatocellular carcinoma, which occupied almost the entire segment 6, with extension into the segment 7 (**Figure 2**), in a 69 year-old patient with virus C liver cirrhosis. IOUS assisted the delimitation of the resection area by guiding the electrocautery marking on the liver surface (**Figure 3**).

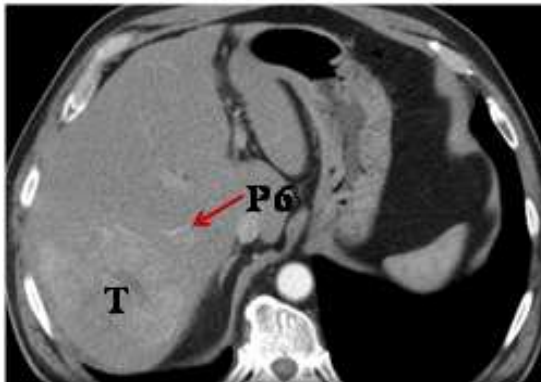

Figure 2. Contrast enhanced computer tomography viewing a hepatocellular carcinoma that includes the segment 6 and partially extends to the segment 7, with contrast uptake in the arterial phase and rapid „wash out” in the portal phase.

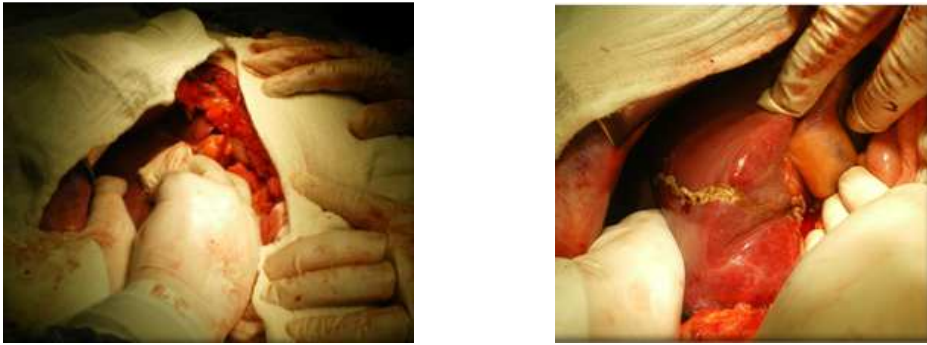


Figure 3. Ultrasound guided marking of the resection area with the electrocautery.

Afterward, IOUS guided the transection plane in such a way that intersected the hepatic pedicle for the segment 6 at the level of its emergence from the posterior right pedicle (**Figure 4**), facilitating the anatomic liver resection of segment 6; the liver transection plane was then directed to the level of the segment 7, partially including it in the resection, ensuring a few millimeters oncologic margins. The resection plane was ultrasound guided so that it preserved the vascularization and the biliary drainage for the remaining liver parenchyma (**Figure 5**).

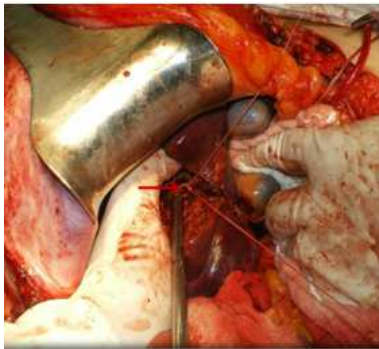


Figure 4. Intraoperative aspect during the hepatic resection. The arrow indicates the pedicle for the segment 6 crossed by the resection plan.

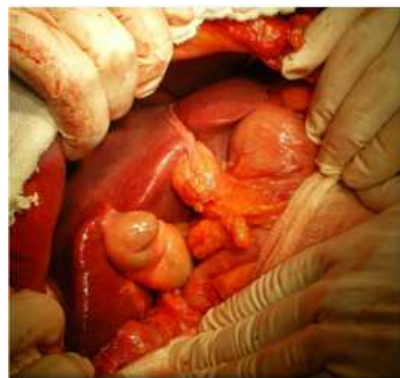
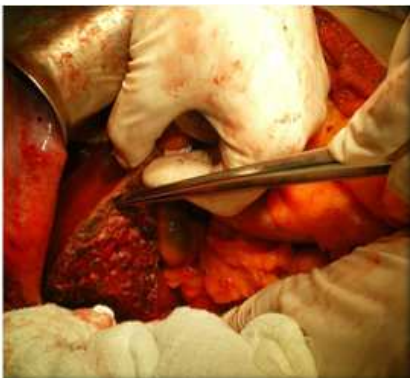
Figure 5. Final aspect of the liver cut surface (left) and the remnant liver (right).

The applications of IOUS in the biliary surgery are presented in **Table 5**.

IOUS offered informations about spleen anatomy, location and staging of splenic hydatid cysts in two cases. One was a 48 year-old patient with multiple splenic hydatid disease with extension to the left diaphragm, associated with a liver hydatid cyst (segment 6) and multiple hydatid cysts located in right renal lodge (in which splenectomy and evacuation of the hepatic and retroperitoneal cysts with partially pericystectomy were performed).

The urological applications of IOUS are presented in **Table 6**.

IOUS in biliary surgery	Applications	Number of cases	%
Diagnosis	Visualization of gallblader lithiasis	9	100,0
	Visualization of common bile duct lithiasis	1	11,1
	Infirmation of common bile duct lithiasis	7	77,8
Interventional	Ultrasound guided extraction of common bile duct lithiasis	1	11,1
	Placement of transhepatic biliary drainage	1	11,1

Table 5. Applications of intraoperative ultrasound (IOUS) in biliary surgery.

IOUS in urologic surgery	Applications	Number of cases	%
Diagnosis	Visualization of renal and basinetal stones	6	100,0
Interventional	Ultrasound guided extraction of renal stones	2	33,3

Table 6. Applications of intraoperative ultrasound (IOUS) in urologic surgery.

5. Milan study group

The studied group, consisting of 356 patients, had a men/women ratio of 257/102, with an average age of 64,9 years (average 67, range 23-87). The surgically treated liver pathology is presented in Table 7.

IOUS with and without contrast detected a total number of 1068 lesions (average 3,2; median 2; range 1 - 48) (**Figure 6**). These were bilobar in 48 cases (21,8%). 23 cases (6,4%) had portal thrombosis of a 1st or 2nd order portal branch (15 cases; 4,2%), and of a 3rd or 4th order portal branch (8 cases; 2,2%).

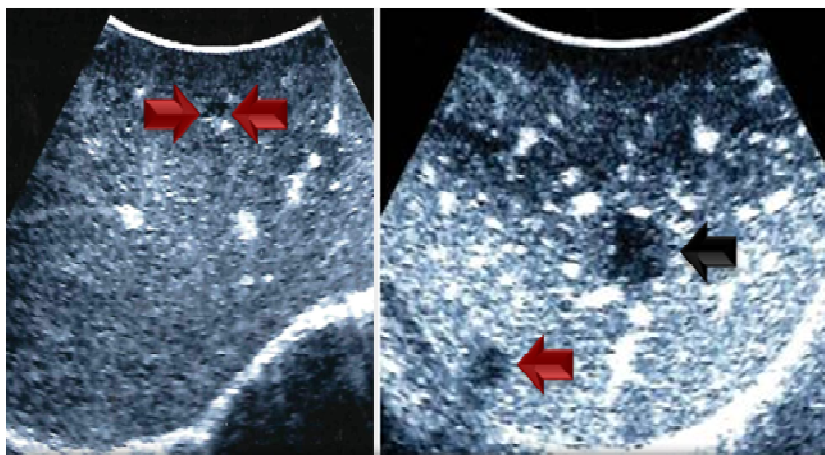


Figure 6. Intra-centimetric metastasis detected by contrast enhanced intraoperative ultrasound (CEIOUS) (colored arrows); the metastasis indicated by the black arrow was previously detected by IOUS

Thoracofrenolaparotomy was used in 68 cases (19%). The types of hepatic resection are presented in Table 8. The exploratory laparotomy rate was 7,3% (26 cases). The operating average time was of 405 minutes (median 377,5; range 65 - 1061), with an average total time of intermittent Pringle maneuver of 78 minutes (median 65; range 12 - 238). The average blood loss was 395ml (median 300; range 50 - 3000) and the blood transfusion rate was of 16,2% (58 cases); the average number of hospitalization days was 10 (median 9, range 4 - 46).

The postoperative morbidity rate was 23,2% (83 cases); major complications were recorded in 6,4% (23 cases) and minor complications in 16,8% cases (60 cases). The major complications consisted in medium and severe hepatic failure in 8 cases (2,2%), liver and renal failure in 4 cases (1,1%), hemoperitoneum in 3 cases (0,8%), acute pulmonary edema in 2 cases (0,6%), massive pleural effusion in 4 cases (1,1%) and perihepatic abscess and high flow biliary fistula in one case (0,3%). The biliary fistula rate (defined as the persistence of biliary secretion in the abdominal drainage after more than 7 days) was of 2,5% (9 cases). The reintervention rate was of 1,4% (5 cases): hemoperitoneum (3 cases), portal thrombosis (1 case) and evisceration (1 case). The postoperative mortality rate was 1,1% (4 cases): 3 cases due to serious hepatic failure and 1 case due to multiple system and organ failure.

Table 9 presents the sensitivity, specificity, the negative and positive values and the accuracy of the preoperative imagistic investigations (CT/MRI), IOUS and CEIOUS in patients with CRM. CT and MRI had a sensitivity, specificity and a negative predictive value significant inferior to IOUS and IOUS combined with CEIOUS.

Hepatic surgical pathology		Number of cases	%
Neoplastic tumors 345 patients	Hepatocellular carcinoma	179	50,1
	Metastasis	152	42,6
	With colo-rectal origin	122	34,2
	Other origins	30	8,4
	Cholangiocarcinoma	12	3,4
	Hemangioendotelioma	2	0,6
Benign tumors 12 patients	Hemangioma	1	0,3
	Adenoma	5	1,4
	Focal nodular hyperplasia	4	1,1
	Pseudotumors	2	0,6

Table 7. Classification of operated lesions.

Resection types	Number of cases	%
Major resections (≥ 3 segments)	30	8,4
Minor resections	327	91,6
2 segments	38	10,6
1 segment	76	21,3
Limited associated resections	28	7,8
Limited resections	213	59,7
Single	108	30,3
Multiple	105	29,4

Table 8. Types of ultrasound guided hepatic resection.

Parameters	CT/RMN (%)	USIO (%)	USIO + CEIOUS (%)
Sensitivity	59.9	87.3	90.1
Specificity	0	13.3	100
Positive predictive value	6	10	100
Negative predictive value	0	90	99
Accuracy	60.3	90	90

Table 9. Sensitivity, specificity, negative and positive predictive values and the accuracy of the preoperative imagistic investigations (CT/RMN), USIO and CEIOUS at patients with colorectal liver metastasis CRM.

Guiding the hepatic resections, IOUS assisted the surgical treatment of complex malignant hepatic tumors:

- Systematic extended right posterior sectionectomy (SERPS) (41 patients; 11,5%) for tumors related to right hepatic vein (at the hepatocaval confluence) and/or the branches of the right portal vein (at the origin) (**Figures 7, 8**);
- minimesohepatectomy (16 patients, 4,5%) for tumors related to medial hepatic vein (MHV), at its hepatocaval confluence (**Figure 9**);
- Ultrasound guided hepatic resections for tumors with central location (related with the major portal branches – the right portal vein with its two main branches and the left portal vein) (64 patients; 17,9%) (**Figure 10**);
- Ultrasound guided hepatic resections in one operative session in multiple bilobar metastasis (26 patients, 7,3%);
- segmentectomy/subsegmentectomy in hepatocellular carcinoma on liver cirrhosis (14 and 22 cases, respectively; 4% and 6,2%, respectively) (**Figure 11**).

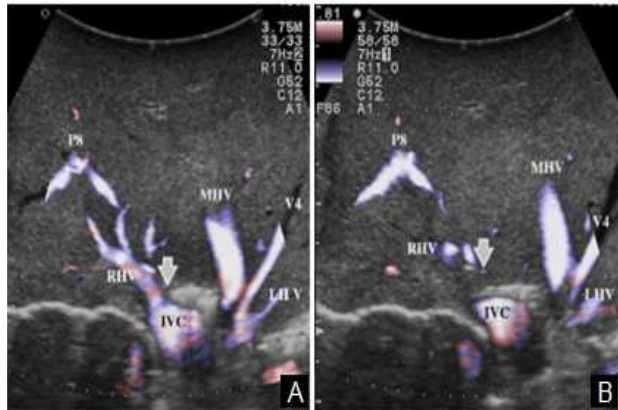


Figure 7. eFlow before (A) and during the ultrasound guided digital compression of right hepatic vein (RHV) (B) (săgeți). The inversion of the flow in RHV with preservation of hepatopetal flow in P8 ventral and dorsal (P8v și P8d) can be observed. MHV – medial hepatic vein; LHV – left hepatic vein; IVC – inferior vena cava.

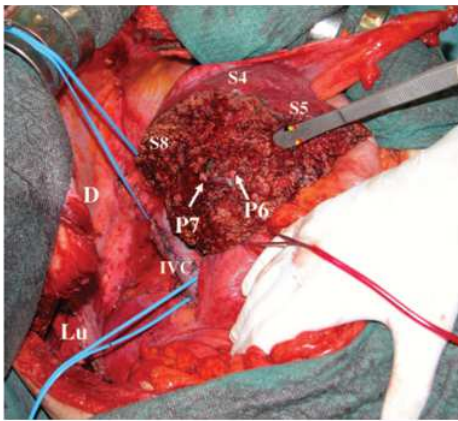


Figure 8. Final intraoperative aspect after systemic extended right posterior sectionectomy (sectorectomy) (SERPS) for a hepatocellular carcinoma invading the right hepatic vein (RHV) at its hepatocaval confluence: resection of 6 and 7 segments extended to 8 segment with the RHV. The ligated stumps of P7 and P6 can be seen on the liver cut surface. IVC – inferior vena cava, D – diaphragm, Lu – right lung.

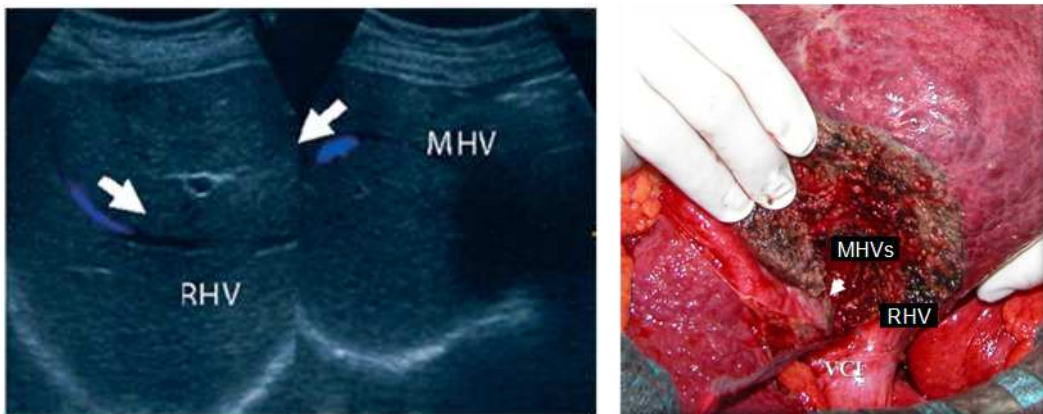


Figure 9. Intraoperative ultrasound at the same patient: the Doppler intraoperative examination describes the collateral circulation between the right hepatic vein (RHV) and the medial hepatic vein (MHV) after the ultrasound guided compression of the MHV; the flow in the distal portion of the MHV is inverted (hepatopet). Intraoperative aspect postresection at the same patient: the stump of the medial hepatic vein (MHVs) can be seen on the transe. RHV – right hepatic vein.

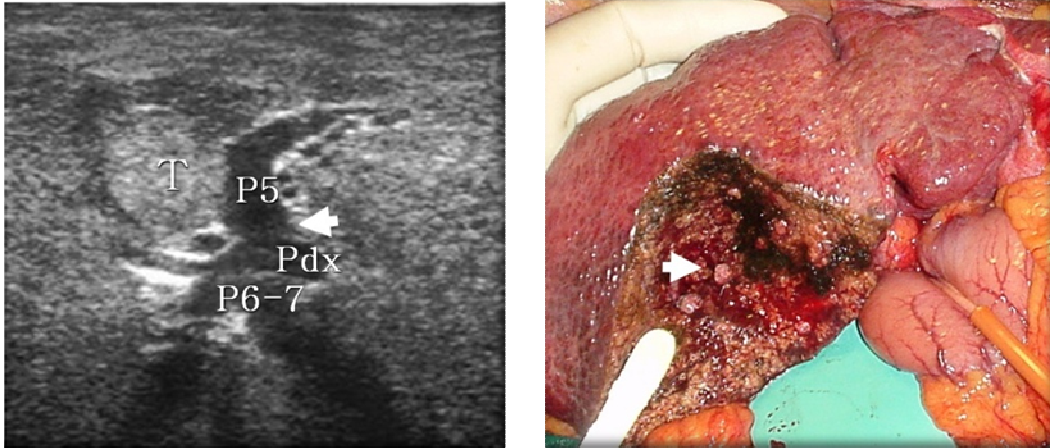


Figure 10. Central hepatocarcinoma (T) (right group) with type II Hi raport with P5. Intraoperative ultrasound (left) and intraoperative postresection aspect (right); the hepatic resection consisted in segmentectomy S5, with the preservation of P6-7 and P8. The arrow indicates the level of ligation of P5 (left) and the blunt of P5 exposed on the transe (right).

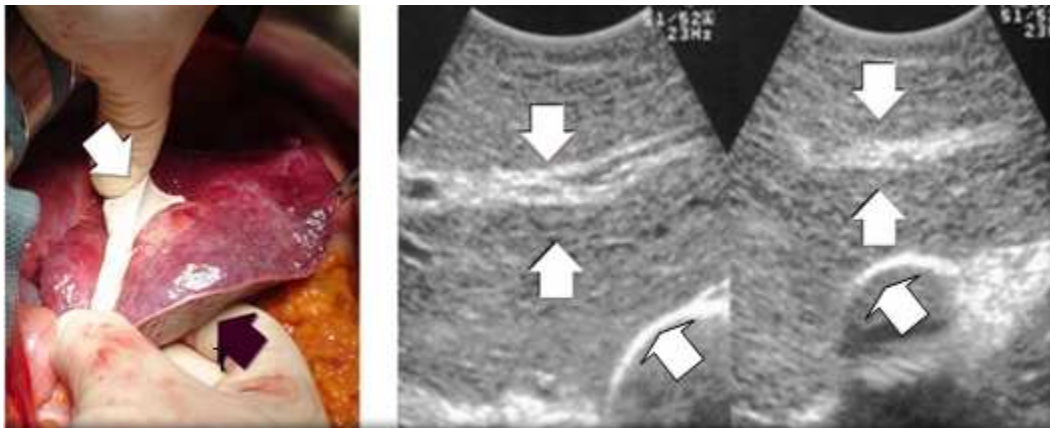

Figure 11. The ultrasound guided compression of P3 for a hepatocellular carcinoma (T) in S3. Intraoperative aspect (left) with microconvex probe that spots P3 and comprises it by digital ultrasound guided contracompression (oblique arrows); it can be observed the blue aspect of S3 produced by the ischemia induced by the ultrasound guided compression. IOUS aspect (right) with P3 (vertical arrows) placed between the ultrasound probe and the index of the surgeon and afterwards closed by the compression between them.

6. Discussions

Diagnostic applications of intraoperative ultrasound

There are few on IOUS in the diagnosis of hepatic fluid collections. IOUS was used for obtaining informations on the precise staging of hydatidic cysts, for the study of pericyst [5] and for establishing their relationships with the vascular and biliary structures [6]. Furthermore, IOUS was used to locate invisible and non palpable cysts, like small size and deep ones [7], especially in the case of multiple hepatic hydatidic disease [8]. The diagnostic intrathoracic transdiaphragmatic IOUS, which we used for the IOUS exploration of liver and spleen during thoracic surgery, represents an original application.

In our experience, on the largest group of patients in the literature, the diagnostic applications of IOUS mentioned above have fully proven their utility, successfully completing the necessary informations during surgery. In 31 cases (64,6%), even with complex presentation of hydatidic disease, we did not considered necessary to make other additional preoperative imagistic investigations other than abdominal ultrasound. In hepatic abscesses, IOUS was useful in making the diagnosis, including the differential diagnosis with infected hydatidic cyst, having a sensitivity and specificity of 100%. In all operated cases for fluid collections (57 patients), IOUS visualized the vascular and biliary structures in their proximity.

Liver IOUS has become a standard adjuvant method in the hepatic resection for primitive tumors and also for metastasis [9, 10, 11, 12]. IOUS assures a spatial resolution superior to CT or MRI, having a definite role in choosing the parenchymal dissection plan in hepatic resections [13]. IOUS can detect additional metastasis to those diagnosed preoperative, avoiding the incomplete hepatic resections or contraindicating the hepatic resection when it is impossible to achieve the objective of complete resection of tumoral tissue.

IOUS optimizes the hepatic resection procedures by detecting all the lesions and by assuring the optimal resection margins, increasing in this way the survival rate of the patients. Furthermore, recent studies have shown the benefit of IOUS in establishing the optimal resection plan, with the achievement of appropriated oncological security margins proven on the resected specimen [14, 15].

The intraoperative ultrasound guidance of surgical maneuvers

The ultrasound guidance of the surgical approach of liver fluid collections is a concept rarely encountered in literature, existing reports only on hydatid disease (but not on abscess). Thus, Dervisoglu and collaborators [8] used IOUS to locate biliary - cystic fistulas, application that we also successfully used in 6 cases (12,5%). Another ultrasound guided application is the total pericystectomy [5].

Intraoperative PAIR (punction - aspiration - inactivation - reaspiration) represents a minimally invasive technique which has proven its utility in case of deep hydatidic cysts; this technique was used in open surgery [2] and also in laparoscopy [17].

In our study we had 4 cases of hepatic hydatid disease (8,3%) in which we successfully used this technique. The reduced invasiveness and execution time, the alternative being hepatic resections or complex hepatotomy, recommend the use of this technique in such cases. Furthermore, we applied the intraoperative PAIR technique in the case of deep abscesses (2 patients - 22,2% of cases with liver abscesses), the „inactivation” of the septic content being achieved by repeated injection of Betadine diluted in sterile saline solution; this represents a new application of IOUS.

With the help of intraoperative ultrasound, we devised new techniques for approaching fluid collections, consisting of transcavitary or transdiaphragmatic approach. The transvacitrary approach was used in deep liver fluid collections (hydatid cysts and abscesses), in cases of multiple liver fluid collections. In cases with multiple hydatid disease, the technique started with ultrasound guided puncture for inactivation. The approach of fluid collections was accomplished in two ways, depending on the topography of the remaining cavities related to the deep approachable formation. In the case of remaining cavities situated on the diaphragmatic side and the inferior border of the liver, with wide access at their level, cystotomy was made with electrocautery which was positioned by ultrasound guidance on the surface of the remaining cavity. In case of remaining cavities located on the visceral side of the liver, cystotomy was made with the help of a Pean clamp introduced transcavitary, under ultrasound guidance that located the avascular septum situated between the deep collection and the remaining cavity. The optimal results, the lack of intraoperative incidents and major postoperative complications, and the good postoperative results recommend the use of this technique.

The transdiaphragmatic approach of the fluid hepatic collections consisted in making an ultrasound guided frenotomy centered on the fluid collection (located at the level of the liver dome), during surgery for right pulmonary pathology. This technique also represents a new application of IOUS; in our experience, the pathology consisted in pulmonary and hepatic hydatid disease (3 cases), and in pachypleuritis and hepatic abscesses (1 case). The limited frenotomy allowed the treatment of both pulmonary and hepatic pathology in the same operatory session, with fast postoperative recovery.

Although there still are skeptical opinions related to the utility of the IOUS in hepatic surgery [18], many studies have clearly proven its value, stating that the modern hepatic resections have to be ultrasound-guided. Since 1979, it has been observed that the conventional hepatic resections in cirrhotic patients have a great rate of postoperative complications, mainly due to hepatic failure (up to 64% of cases) [19]. The possibility of making anatomical hepatic resections, especially in patients with hepatocellular carcinoma on liver cirrhosis, without mortality or major complications [20], due mainly to the use of IOUS [21], which is the best im-

aging method for tumor staging at hepatic level and for the step by step guiding of the parenchymal transection. It has to be stressed out that segmentectomy or subsegmentectomy in hepatocellular carcinoma has proven to be superior in terms of local recurrence in comparison to limited atypical resection [11, 13]. A supplementary confirmation of the value of IOUS in guiding liver resection is given by the fact that the margins of resected specimens have been infiltrated at 16-18% of patients with hepatic resections non-assisted by ultrasound, a superior percentage compared to the ones recorded after ultrasound guided resections [22, 23].

Systematic extended right posterior sectionectomy (SERPS) [24] allowed avoidance of right hepatectomy in 10% of patients, a higher percentage than one of the right hepatectomy (9%). The main advantage of SERPS is the preservation of the majority of hepatic parenchyma of the anterior right section (sector) (segments 5 and 8), which is the largest liver section [25], avoiding the risk of post-operative hepatic failure caused by the insufficient residual hepatic volume.

Minimesohepatectomy [26] was performed in patients who would have had as surgical indication trisectionectomy (trisectionectomy) or mesohepatectomy, these having tumors with macroscopic invasion of the medial hepatic vein at its hepatocaval confluence. This technique requires a much reduced surface resection compared with mesohepatectomy. By avoiding a major resection, this technique allows the preservation of majority of major vascular structures, offering the possibility of a subsequent resection in case of recurrences [27, 28].

In central tumors, IOUS has made possible parenchymal preservation, avoiding major hepatectomies despite the complexity of the cases; thus, right hepatectomy was performed in only 4,7% of cases, and the left one only in 3,1% of cases, central hepatectomy not being necessary in none of the cases. Ultrasound guided resections led to obtain security margins of 0mm in 40,6% of cases (26 patients), which is not an alarming fact because there are studies which support the efficiency of the resection with reduced oncological security margins, without a greater risk of local recurrences [29, 30]. The advantage of such conservative procedure is the possibility to perform new resections for recurrences, with impact on the overall survival time [31]; so, preserving the major vascular structures after liver resection, allows surgical solutions for the future recurrences, which is usually impossible after major hepatectomies.

The ultrasound guided resection for multiple bilobar metastasis in one operative session has proven to be superior compared to two-stage hepatectomy regarding mortality and morbidity [32]. The strategy and surgical technique used in our study don't seem to increase the risk of postoperative recurrence, 54% of patients developing new lesions during the postoperative follow up (50% with hepatic disease), in comparison to 64% (48% with hepatic disease) reported by Jaeck and al [33], and 69% (61% with hepatic disease) reported by Adam and al [34].

7. Conclusions

IOUS makes a precise and a real time study of the anatomy of the parenchymatous organs (hepato - biliary - pancreatic region, kidneys, spleen) and of the retroperitoneum, allowing the evaluation of the anatomical relationship with the lesion to be operated. Due to superior diagnostic precision in comparison to CT/MRI, in selected cases, IOUS can substitute them in surgical emergencies or in situations in which they are not available in time.

The applications of the IOUS are mainly in the surgical pathology of liver, but are also useful in the biliary - pancreatic, renal and splenic surgical diseases.

In liver fluid collections (hydatid cysts and abscesses), IOUS locates the lesions and makes a precise diagnosis. Furthermore, IOUS assists the surgical approach of these lesions, with the help of some original techniques (ultrasound transcavitary guided cystotomy, intrathoracic transdiaphragmatic ultrasound, ultrasound guided frenotomy), and other less used techniques in surgical practice (ultrasound guided cystotomy / hepatotomy, intraoperative PAIR). These techniques have the advantages of reduced invasiveness, low risk of intraoperative incidents and a diminished rate of postoperative complications, eliminating the necessity of hepatic resection even in complex cases. In biliary and renal lithiasis, IOUS detects the stones, representing an alternative to the intraoperative radiological explorations. Also, IOUS facilitates the surgical maneuvers of lithotomy by locating the stones in real time.

IOUS is superior to CT/MRI in staging the neoplastic hepatic diseases, in detecting the lesions, in the evaluation of the tumoral dimensions and in diagnosing the criteria of advanced neoplasia. In hepatic tumors, the use of IOUS in guiding resections reduces the rate of major hepatectomies, of vascular reconstruction and even the need for preoperative venous portal embolization, with the reduction of intraoperative incidents, postoperative complications and blood transfusions. In this way, IOUS allows making new conservative resections, such as systematic right posterior sectionectomy (sectorectomy) (as an alternative to right hepatectomy) and minimesohepatectomy (as an alternative to trisectorectomies or central hepatectomy). It also allows the resection of a great number of tumors in one operative session, offering an alternative to the two-stage hepatic resection.

CEIOUS allows a precise staging of hepatic tumors, assuring a more efficient surgical treatment. The use of IOUS with and without contrast substance in hepatocellular carcinoma on hepatic cirrhosis makes possible the hepatic resection in more advanced stages that currently recommended. The IOUS is a method of diagnosis and guidance of surgical procedures, which has to be part of the modern abdominal surgery arsenal in generally, and of hepatic surgery in particular, being optimally exploited when performed by the surgeon.

R E F E R E N C E S

- [1] Makuuchi M, Hasegawa H, Yamazaki S, et al. *Newly devised probe for intraoperative ultrasonic examination*. Image Technol Info Display Med 1979; 11:1167-1169.
- [2] Botea F, Sârbu V, Dima S, Iusuf T, Unc O, Toldișan D, Pasăre R. *The role of intraoperative ultrasound in the diagnosis and treatment of hydatid liver disease*. Chirurgia (Bucur). 2006 Nov - Dec; 101(6):593-8.
- [3] Torzilli G, Del Fabbro D, Palmisano A et al. *Contrast-enhanced intraoperative ultrasonography during hepatectomies for colorectal cancer liver metastases*. J Gastrointest Surg. 2005 Nov; 9(8):1148-53; discussion 1153-4.
- [4] Kane RA, Escluso A. *Intraoperative ultrasound*. In: Wilson S R, Charboneau J W, Leopold G R, eds. *Ultrasound: categorical course syllabus*. Presented at the American Roentgen Ray Society 93rd Annual Meeting, San Francisco, 1993: 241–250.
- [5] Ivanov SA, Kotiv BN. *Ultrasound examination in the surgery of hepatic echinococcosis*. Vestn Khir Im I I Grek. 2001; 160(3):73-7.
- [6] Gavrilin AV, Vishnevskii VA, Ikramov RZ, Ambadi V. *Intraoperative ultrasonic study in surgery of hepatic echinococcosis*. Khirurgiia (Mosk). 1991 Feb; (2):78-82.
- [7] Picardi N, Annunziata A, Bartolacci M, Di Rienzo M, Bottegoni G, Zuccarini F, Visini R. *The radical treatment of hepatic hydatidosis with deep and multiple locations. The role of new technologies particularly in the case of multiple locations*. Ann Ital Chir. 1999 Jul - Aug; 70(4):529-38.
- [8] Dervisoglu A, Erzurumlu K, Taç K, Arslan A, Gürsel M, Hökelek M. *Should intraoperative ultrasonography be used routinely in hepatic hydatidosis?* Hepatogastroenterology. 2002 Sep - Oct; 49(47):1326-8.
- [9] Popescu I, Tulbure D, Ionescu M, et al. *Rezețiile hepatice: indicații, tehnică, rezultate*. Chirurgia, 2003, 98 (1):34-40.
- [10] Staren ED, Escluso A. *Intraoperative ultrasound*. In Staren ED, Arregui M (eds): *Ultrasound for the Surgeon*. Philadelphia, Lippincott-Raven Press, 1996.
- [11] Makuuchi M, Takayama T, Kosuge T et al. *The value of ultrasonography for hepatic surgery*. Hepatogastroenterology, 1991, 36:64.
- [12] Machi J, Isomoto H, Kurohiji T et al. *Accuracy of intraoperative ultrasonography in diagnosing liver metastasis from colorectal cancer: Evaluation with postoperative follow-up results*. World J Surg, 1991, 15:551.

- [13] Torzilli G, Olivari N, Moroni E et al. *Contrast-enhanced intraoperative ultrasonography in surgery for hepatocellular carcinoma in cirrhosis*. Liver Transpl. 2004 Feb; 10(2 Suppl 1):S34-8.
- [14] Castaing D, Emond J, Bismuth H, Kunstlinger F. *Utility of operative ultrasound in the surgical management of liver tumors*. Ann Surg, 1986, 204:600-605.
- [15] Lau WY, Leung KL, Lee TW, Li AKC. *Ultrasonography during liver resection for hepatocellular carcinoma*. Br J Surg 80:493-494, 1993.
- [16] Tasev V, Ionkov A. *Intraoperative echography in the diagnosis and treatment of minor intraparenchymal cysts in multiple hepatic echinococcosis--a report on 3 cases*. Khirurgia (Sofia). 1998; 51(3):25-7.
- [17] Trotta F, Prati U, Roveda L, Brunetti E, Filice C. *Intra-operative PAIR of hepatic echinococcal cyst after cholecystectomy with laparoscopic approach*. Liver Int. 2007 Mar; 27(2):284-6.
- [18] Finlayson C, Hoffman J, Yeung R, et al. *Intraoperative ultrasound does not improve detection of liver metastases in resectable pancreatic cancer*. Am J Surg 1998; 175:99-101.
- [19] Lin TY, Escluso A. *Resectional therapy for primary malignant hepatic tumors*. In: Murphy GP, editors. International Advances in Surgical Oncology New York: Alan R Liss 1979. p. 25-54.
- [20] Torzilli G, Makuuchi M, Inoue K, et al. *No-mortality liver resection for hepatocellular carcinoma in cirrhotic and noncirrhotic patients: is there a way? A prospective analysis of our approach*. Arch Surg 1999; 134:984-92.
- [21] Makuuchi M, Escluso A. *Abdominal Intraoperative Ultrasonography*. Tokyo- New York: Igaku-Shoin; 1987.
- [22] Lau WY, Leung KL, Lee TW, et al. *Ultrasonography during liver resection for hepatocellular carcinoma*. Br J Surg 1993; 80:493-4.
- [23] Lai EC, Ng IO, Ng MM, et al. *Long term results of resection for large hepatocellular carcinoma: A multivariate analysis of clinicopathological factors*. Hepatology. 1990; 11:815-818.
- [24] Torzilli G, Donadon M, Marconi M, Botea F, Palmisano A, Del Fabbro D, Procopio F, Montorsi M. *Systematic extended right posterior sectionectomy: a safe and effective alternative to right hepatectomy*. Ann Surg. 2008 Apr; 247(4):603-11.
- [25] Abdalla EK, Denys A, Chevalier P, et al. *Total and segmental liver volume variations: implications for liver surgery*. Surgery. 2004; 135: 404-410.

- [26] Torzilli G, Botea F, Donadon M, Cimino M, Del Fabbro D, Palmisano A. *Minimesohepatectomy for Colorectal Liver Metastasis Invading the Middle Hepatic Vein at the Hepatocaval Confluence*. *Ann Surg Oncol*. 2009 Oct 23.
- [27] Suzuki S, Sakaguchi T, Yokoi Y, et al. *Impact of repeat hepatectomy on recurrent colorectal liver metastases*. *Surgery*. 2001; 129:421-428.
- [28] Nakajima Y, Ko S, Kanamura T, et al. *Repeat liver resection for hepatocellular carcinoma*. *J Am Coll Surg*. 2001; 192:339-344.
- [29] Lang BH, Poon RT, Fan ST, Wong J. *Perioperative and long-term outcome of major hepatic resection for small solitary hepatocellular carcinoma in patients with cirrhosis*. *Arch Surg*. 2003; 138:1207-1213.
- [30] Kokudo N, Miki Y, Sugai S, et al. *Genetic and histological assessment of surgical margins in resected liver metastases from colorectal carcinoma: minimum surgical margins for successful resection*. *Arch Surg*, 2002; 137(7): 833-40.
- [31] Minagawa M, Makuuchi M, Torzilli G, et al. *Extension of the frontiers of surgical indications in the treatment of liver metastases from colorectal cancer: long-term results of our experience*. *Ann Surg*, 2000; 231(4): 487-499.
- [32] Torzilli G, Procopio F, Botea F, et al. *One-stage ultrasonographically guided hepatectomy for multiple bilobar colorectal metastases: a feasible and effective alternative to the 2-stage approach*. *Surgery*. 2009 Jul; 146(1):60-71.
- [33] Jaeck D, Oussoultzoglou E, Rosso E, et al. *A two-stage hepatectomy procedure combined with portal vein embolization to achieve curative resection for initially unresectable multiple and bilobar colorectal liver metastases*. *Ann Surg*. 2004; 240:1037-1049.
- [34] Adam R, Laurent A, Azoulay D, et al. *Two-stage hepatectomy: A planned strategy to treat irresectable liver tumors*. *Ann Surg*. 2000; 232: 777-785.

Abbreviations

IOUS – intraoperative ultrasound

CEIOUS – contrast enhanced intraoperative ultrasound

CT – computed tomography

MRI – magnetic resonance imaging

SERPS – systematic extended right posterior sectionectomy (sectorectomy)

RHV – right hepatic vein;

MHV – medial hepatic vein

LHV – left hepatic vein;

IVC – inferior vena cava

CRM – colorectal liver metastasis.